

Experimental Study on Anti Scorpion Venom potential of *Paravatadi Agada* of Ayurveda in Indian Red Scorpion Venom (*Mesobuthus tamulus*)

Research Article

Sunil Deshmukh¹, Sonali Chalkh^{2*}, Dhirajsing Rajput³

1. PG Scholar, 2. Professor, Department of Agad Tantra, 3. Associate Professor, Department of Rasashastra, Mahatma Gandhi Ayurveda College, Hospital and Research Centre, Datta Meghe Institute of Medical Sciences, Salod (H), Wardha, Maharashtra.

Abstract

Background: Scorpion sting is a frequent event in tropical and subtropical countries. The objective of this study is to evaluate Efficacy of *Paravatadi Agada* on Indian Red Scorpion Venom (*Mesobuthus Tamulus*). **Materials and Methods:** PA was prepared as per textual reference. Water soluble extract of PA was obtained using Soxhlet apparatus. Swiss albino mice of 20-30gm were used. Lyophilised venom sample of *Mesobuthus tames* and Lyophilized monovalent enzyme refined immunoglobulin anti scorpion venom serum (ASV) was used. Using lethal dose of scorpion venom (25.12 µg/g), venom neutralising property of PA extract (300mg/kg), ASV(1mg) intra-peritoneally and PA(31mg/mice) orally. The parameter used were Mean survival time, protection fold and percentage survival of animals over the period of 24 hrs. Histopathological examinations of all mice were done. **Result:** Maximum protection fold is seen in ASV treated group which is 10.03 with 83.33 % survival but water soluble extract of PA also showed some protective effect against scorpion venom 7.68 with 50 % survival rate. Histopathological examination showed that PA extract, ASV and PA treated group showed less effect of scorpion venom on Heart, Liver and Kidney compared to control group in which sever histopathological manifestations are detected. **Conclusion :** The protection fold and survival percentage of extract of PA was better than Powder form of PA but less than ASV but enough significant in view of availability, safety, ease in method of preparation and cost effectiveness compared to ASV.

Key Words: Scorpion sting, *Paravatadi Agada*, Indian red scorpion venom, Anti-scorpion venom.

Introduction

Scorpion sting is a frequent event in tropical and subtropical countries (1). It is estimated that in India the annual number of scorpion stings cases exceeds 1.23 million, of which over 32,250 may be fatal. India is the most affected, with a reported incidence of 0.6% (2) These are found in large quantity in western Maharashtra, Parts of Karnataka, Andhra Pradesh, Saurashtra, Pondicherry and Tamil Nadu (3). In India severe scorpion sting due to *Mesobuthus tames* species of scorpion is mainly found in Kokan region (4). Higher incidence of scorpion sting occurred during hot months attributed to increase in agricultural activity(5,6). Scorpion venom causes massive release of neurotransmitter which results in clinical features of envenomation (7). Clinical effects of stings are related to age, size of scorpion, season of the sting and time lapsed between sting and hospitalization (8). It is

classified into local manifestation, systemic involvement, Cardiogenic failure (hypotension, ventricular arrhythmia, bradycardia, cardiovascular collapse) and Respiratory failure(cyanosis, dyspnoea, pulmonary oedema) (9). In Ayurveda *Vrishchika*(scorpion) are considered as one of the *kita* which is explained under the context of *Kitvishpratishedha* (10). Various Agada are mentioned in classic for different poisoning cases along with it can be prescribed in the condition other than poisonous incidence. (11). *Paravatadi Agada* (PA) is one of the remedy mentioned in *Astang Hridayam* for the treatment of scorpion bite poisoning and it is narrated that this formulation is best among all other remedies to treat scorpion bite (12). However, efficacy of PA has not been scientifically proved yet. Therefore, present work was undertaken with aim to evaluate the efficacy of PA in the management of Indian Red Scorpion bite on Albino mice.

Materials and Methods

Collection of Raw material

All the ingredients were procured from local market Nagpur. Paravat Shkrut was collected from Poultry farmer, Wardha. Fruit of Bijapurak was collected from Kolhapur. All the drugs were authenticated by subject expert.

* Corresponding Author:

Sonali Chalkh

Professor, Department of Agad Tantra, Mahatma Gandhi Ayurveda College, Hospital and Research Centre, Datta Meghe Institute of Medical Sciences, Salod (H), Wardha, Maharashtra, India
Email Id: spchalkh@gmail.com

Preparation of PA

For the preparation of PA all the crude drugs were made into fine powder and sieved through 80 number mesh. Powdered ingredients were taken in equal quantity in khalvyantra and one Bhavana of Bijapurak swarasa was given.

Table: 1 Ingredient used for the preparation of formulation

Name of the ingredient	Latin Name/ English name	Part used	Quantity
Tagar	<i>Veleriana Wallichii</i> DC	Root	150gm
Haritaki	<i>Terminallia Chebula</i> Retz.	Fruit	150gm
Vishwabhaish alyam	<i>Zingiber Officinale</i> Rosc.	Root	150gm
Bijapurak Swaras	Juice Of <i>Citrus Medica</i> L.	Fruit	150gm
Parawat shakrut (pigeon droppings)	Pigeon droppings		1 lit

Preparation of extract of PA

Water soluble extract was prepared according to the procedure reported by Mahanta and Mukharjee by using Soxhlet apparatus(13). 50 gm of PA taken in 'timble' made of porous cotton bag, is placed in central part and 500 ml water taken in solvent flask and heated it on 60°C to 70°C temperature. To allow proper soaking for better extraction, the mixture was kept for 2 hours. After 2 hour of heating the liquid in solvent flask was boiled at 100 °C, during heating the vapors were condensed in condenser. The condensed extract drips into the timble containing the Paravtadi Agada, extracting it by contact. When the level of liquid in this rises to the top of the siphon tube, the liquid contents of central part was run through siphon into Solvent flask. This process was carried out until a drop of solvent from the siphon tube does not leave residue when evaporated which was observed after continuing the process for five times. The extract thus obtained was dark brown in colour. Then the extract was collected and heated on gas stove at 60 °C till the liquid attained semisolid type consistency and then the heating process was stopped. The extract was taken into Petri dish and dried in oven. The dried extract was dried and powdered and packed into airtight bottle.

Scorpion Venom sample

Lyophilized venom sample of *Mesobuthus tamulus* was purchased from Haffkine Institute, Parel, Mumbai, Maharashtra and was stored at 2-8°C for future use, taking all necessary precautionary measures of handling and storage.

Antiscorpion venom sample (ASV)

Lyophilized monovalent enzyme refined immunoglobulin ASV of *Mesobuthus tamulus* was purchased from Haffkine Bio-pharmaceutical

Corporation Ltd., Parel, Mumbai, Maharashtra and stored at 2-8°C for future use, taking all necessary precautionary measures of handling and storage. Each 1 ml of reconstituted ASV neutralizes not less than 1.0 mg of dried red scorpion venom.

Experimental Animals

Swiss albino mice of either sex weighing 20-30 g were used for the study. They were procured from the animal house of Datta Meghe Institute of Medical sciences, Wardha, Maharashtra. All the animals were kept under standard condition of 25 ± 2°C and relative humidity 50+ 60%. All animals had free access to standard chow and water ad libitum. All Animals were acclimatized to laboratory conditions for 7 days before the start of the study. All the experimental protocol were approved by Institutional Animal Ethics Committee (IAEC) with approval no. DMIMSDU/ IAEC/ 2015-16/006 and performed according to CPCSEA guidelines for care and use of animals. Dose of PA was calculated as per conversion of human dose to experimental animal dose (14).

Acute toxicity of Red Scorpion Venom and its neutralisation by PA

The animals were divided into four groups, each containing six animals. Each animal in all groups were administered LD₉₉ dose of *Mesobuthus tamulus* venom (25.12 µg/g) (15) (Intraperitoneally). Group 1 received Distilled water (0.5ml) intraperitoneally and was considered as control group. Group 2 received Extract of *Paravatadi Agada* (300 mg/kg) intraperitoneally (PA I) and was considered as Test group-1. Group 3 received ASV (1.0 mg) intraperitoneally and was considered as standard group. Group 4 received *Paravatadi Agada* (31 mg/Mice) orally (PA II) and was considered as Test Group-2. All the groups received the same volume of preparation. In all the groups, duration of survival time, protection fold and percentage survival animals over the period of 24 hr were the parameters used.

Histopathological Examination

After Assessing the Survival period up to 24 hour, Survival animals were chloroform anesthetised . All animals were slaughtered and dissected. The Heart, livers, kidneys were collected immediately in order to avoid diagnosis error and placed in formalin (10%formaldehyde in water) as fixative solution. All samples were collected and send to the Histopathology department for histopathological examination.

Statistical analysis

The statistical analysis was done using unpaired student's t test. P < 0.0106 was considered statistically significant

Observation and result

Statistical analysis depicted in Table I indicates that Group II (PA I) showed statistically significant result in compared to Control group (P value 0.005). Similarly Group III (ASV) & Group IV (PAII)

also showed significant difference in comparison to control group (<0.001 and 0.030 respectively). Table 1, 2, 3. When group III was compared with Group II (PA I) and Group IV (PAII) then obtained nonsignificant statistical difference indicating that both Group II and Group IV are almost as effective as ASV. (Table 4,5,6). Maximum protection is found in ASV treated group (Group III) as compared to test group (Group II and IV) and control group (Group I) but Percentage of survival is 50% in both the test group which is nearly equal to ASV group (83.33%). (Table 7)

Twenty-four Mice were used for histological studies; the animals were divided into 4 groups. Mice in control group shows significant changes such as Myolysis & necrosis in Heart, congestion of portal vein, loss of hepatocytes, acute Haemorrhages in liver and interstitial oedema in kidney. Histopathological study of group I (control) showed significant changes in heart, liver and kidney which are almost complete toxic

manifestation of scorpion venom. Pathological manifestations observed in control group such as Myolysis & Necrosis in heart, Congestion of portal/central veins, Loss of Hepatocytes, Acute Haemorrhages in Liver and Interstitial oedema in kidney are detected which suggest the intense poisonous effect scorpion venom. In Test group I, where PA extract is used the changes observed in heart, liver and kidney are less. In third group which was standard also the pathological changes was seen in Heart and liver while the kidney is observed almost normal that means ASV is not 100% effective in preventing effect of poison. In Test group II which was treated by PA few pathological changes such as oedema, inflammation and acute haemorrhage in Heart detected but Vascularity of Heart remains normal which indicate cardioprotective action while Acute Haemorrhages and Inflammatory cell infiltrate are also found in Liver and Mild toxic pathological changes are also observed in Kidney.

Table 1: Comparison of survival time between I & II

Group Name	Intervention	Mean	Std Dev	SEM	Difference	P value	t Value
Group I	Distilled water (DW)	121.333	48.743	19.899	811.667	0.005	3.548
Group II	Extract of <i>Paravatadi Agada</i> (300 mg/kg) PA1	933	558.282	227.918			

Table 2: Comparison of survival time between I & III

Group Name	N	Mean	Std Dev	SEM	Difference	P value	t Value
Group I	6	121.333	48.743	19.899	1096.500	<0.001	4.916
Group III	6	1217.833	544.195	222.167			

Table 3: Comparison of survival time between I & IV

Group Name	N	Mean	Std Dev	SEM	Difference	P value	t Value
Group I	6	121.333	48.743	19.899	699.667	0.03	2.520
Group IV	6	821	678.241	276.891			

Table 4: Comparison of survival time between II & III

Group Name	N	Mean	Std Dev	SEM	Difference	P value	t Value
Group II	6	933	558.282	227.918	284.833	0.392	0.895
Group III	6	1217.833	544.195	222.167			

Table 5: Comparison of survival time between II & IV

Group Name	N	Mean	Std Dev	SEM	Difference	P value	t Value
Group II	6	933	558.282	227.918	112.000	0.761	0.312
Group IV	6	821	678.241	276.891			

Table 6: Comparison of survival time between III & IV

Group Name	N	Mean	Std Dev	SEM	Difference	P value	t Value
Group III	6	1217.833	544.195	222.167	396.833	0.29	1.118
Group IV	6	821	678.241	276.891			

Table 7: Protection fold, Survival animals and Survival percentage against LD₉₉ of the red scorpion venom

Group (N=6)	Protection Fold	Total animals survived/total animals in each group	% of survival
Group – I	-	0/6	0%
Group – II	7.68	3/6	50%
Group – III	10.03	5/6	83.33%
Group – IV	6.76	3/6	50%

Discussion

Indian Red Scorpion (*Mesobuthus tamulus*) belonging to Buthidae family is the most lethal amongst all the poisonous species of scorpions in India. Scorpion venom is a potent sodium channel activator. It causes, delay in closing of neuronal sodium channels, which results in “autonomic storm” leading to sudden pouring of endogenous catecholamine’s into circulation leading to transient sympathetic and parasympathetic stimulation (16). In India since 1997 Antiscorpion venom is available for scorpion sting (17). Various studies conducted shows that 1ml of reconstituted ASV serum neutralized 1.2mg of Indian red scorpion venom by IV route in vivo study in mice (18).

In the present study when LD₉₉ of Scorpion venom is injected observed mean survival time (in minutes) in group I, II, III and IV is 121.333± 48.743, 933.000 ± 558.282, 1217.833± 544.195 and 821.000 ± 678.241 respectively. Mean survival time of PAI extract treated group (Group II) is considerably nearer to ASV treated group means ASV and PA extract treated group showed significant scorpion venom neutralizing action. However, this action is detected less in PAII group. (group IV)

The ingredients of *Paravatadi Agada* have the necessary actions which are needed in treating scorpion bite. *Haritaki* is *Rasayana*, *Balya*, *Vayasthapana*, *Ayusya*, *Sarvaroga prasamana*, *Anulomana*, *Grahi*, *Medya*, *Hridya*, *Deepana*, *Chakshushya*, *Medohara*. (19) It works as Stomachic, Tonic, Carminative, Expectorant, Laxative, Astringent, Good in eye diseases, Disease of heart and the bladder. (20) It has Cardio- protective, Wound healing, Hepatoprotective activity. (21,22,23) *Tagara* is *Vataghna* and *Tridosahara*. (24) It is useful in treating anxiety, breathlessness, epilepsy, giddiness and fainting fits. The herb lowers blood pressure, palpitation of the heart and even strengthens the heart. It proves helpful in treating head congestion and loosens phlegm in different cough and lung congestion. (25) It have Analgesic, Anti inflammatory and Antioxidant activity. (26,27) *Sunthi* is *Anulomana*, *Pachana*, *Dipana*, *Vatakaphahara*, *Bhedana*, *Hrudya*, *Svarya*. (28) It is used in the prophylaxis of nausea and vomiting associated with motion sickness, Dyspepsia, flatulence, seasickness and as a narcotic antagonist, and as an anti –inflammatory agent in the treatment of migraine headache and rheumatic and muscular disorders. (29,30,31,32) *Bijapur Nimbu* is *Kanha Sodhaka*, *Chardigrahan*, *Dipana*, *Hridya*, *Jihvasodhaka*, *Kaphahara*, *Medhya*, *Pittahara*, *Vatahara*. (33) It has Analgesic and Cardioprotective activity. (34,35) *Paravat Shakrut* is *Kaphapittashamak* and *Raktapittashamaka*. (36)

Histopathological study of group I (control) showed significant changes in heart, liver and kidney which are almost complete toxic manifestation of scorpion venom. Pathological manifestations observed in control group such as Myolysis & Necrosis in heart, Congestion of portal/central veins, Loss of Hepatocytes, Acute Haemorrhages in Liver and Interstitial oedema in kidney are detected which suggest the intense poisonous effect scorpion venom. [Figure 1 (1.1 to 1.6)]

In Group- II pathological changes in Heart such as Oedema, Myolysis & Necrosis, Inflammation and Acute Haemorrhages are evident from histopathological findings. In this group, Liver of four animals showed Congestion of portal/central veins & sinuses; Loss & Necrosis of Hepatocytes (Toxic necrosis); Acute Haemorrhages and Inflammatory cell infiltrate which can be considered as toxic effect of scorpion venom. Rare hyperaemia in Kidney due to changes within glomeruli, focally positive changes within Tubules including Ischemic necrosis & Tubule cell swelling and Infiltrate of leucocytes & eosinophils are also detected in histopathological study of Kidney of this group. In comparison to control group, the changes observed in Heart, Liver and Kidney are enough to suggest that extract of *Paravatadi Agada* have considerable positive effect of scorpion venom. [Figure 2 (2.1 to 2.6)]

In Group- III (Standard Group) ASV was administered which is standard line of management of scorpion bite. However, few pathological changes are detected in Heart, Liver and Kidney especially in S5. The reason is unknown but compared to heart and liver, the changes observed in Kidney are almost normal. This may be due the less pharmacological action of scorpion on Kidney as most of the concentration of scorpion venom gets absorbed while passing through Heart and Liver. Still the pathological finding in Heart and Liver suggests that ASV is not 100 % effective in preventing effect of scorpion venom. [Figure 3 (3.1 to 3.6)]

Group- IV was treated with *Paravatadi Agada*. Few pathological changes such as oedema, Inflammation and Acute Haemorrhages in Heart are detected in histopathological study of few animals. However Vascularity of heart remains normal which indicate cardio-protective action but the range of this action seems limited. Similarly, Congestion of portal/central veins & sinuses, Loss of Hepatocytes (Toxic necrosis), Acute Haemorrhages and Inflammatory cell infiltrate are also found in Liver of *Paravatadi Agada* treated group. Mild toxic pathological changes are also observed in Kidney. [Figure 4 (4.1 to 4.6)]

Hence it can be concluded that ASV as well as PA extract and PA have scorpion venom neutralizing action. However, in findings of present study ASV is said to be have better efficacy than both PA and PA extract .it is also observed that PA extract has better effect than PA. This may be due to fine constituent and low molecular chemicals present in extract which are not in more proportion in powder form.

As experimental animal studies have limitations such as the pharmacodynamic and pharmacokinetic of medicine may vary in human compared to animal. More importantly Ayurveda way of treating is based on individual personality assessment (which is known as *Prakruti*) as well as thorough following specific dietary guidelines. These dietary guidelines are helpful in influencing drug action as well as in reducing the effect of etiological factors. (37) Here it can be claimed that the observed less but significant effect of PV extract compared ASV can be further improved with dietary regimen or administration of other similar formulation having anti-scorpion venom action. However, further

studies are required to access the precision in aforementioned claim.

Conclusion

The protection fold and survival percentage of PA extract (7.68% and 50% respectively) are enough significant in view of availability, compared to ASV which have protection fold 10.03 and survival percentage 83.33. Extract of PA is better effective than powder form of PA but it is comparatively less effective than ASV. Therefore, based on the observed effect, extract of PA can also be utilized in case red scorpion bite, however further repetition of similar work by increasing concentration of extract may provide more valid and applicable outcome.

Reference

- Santhanakrishnan BR, Rangnathan G, Ananthasubramanian P. Cardiovascular manifestation of scorpion stings in children. *Indian Pediatrics* 1977; 353-356.
- Chippaux JP, Goyffon M. Epidemiology of scorpionism: a global appraisal. *Acta tropica*. 2008;1;107(2):71-9.
- Maled V, Dixit U. Profile of scorpion envenomation in Rural India. *Journal of Indian Academy of Forensic Medicine*. 2016;38(4):446-8.
- Bawaskar HS, Bawaskar PH. Treatment of envenoming by *Mesobuthus tamulus* (Indian red scorpion). *Transactions of the Royal Society of Tropical Medicine and Hygiene*. 1992;1;86(4):459-.
- Bawaskar HS. Scorpion Sting: Clinical Manifestations, Management, and Literature. Popular Prakashan; 1999, p.120
- Bawaskar HS and Bawaskar PH. Indian scorpion envenoming. *Indian J Pediatr* 1998;65:383-91.
- Natu VS, Kamerkar SB, Geeta K, Vidya K, Natu V, Sane S, Kushte R, Thatte S, Uchil DA, Rege NN, Bapat RD. Efficacy of anti-scorpion venom serum over prazosin in the management of severe scorpion envenomation. *Journal of postgraduate medicine*. 2010;1;56(4):275.
- Ouanes –Basbes I, Elatrous S, Aubrey N, Eiayeb M and Abroug F. Direct vs mediated effects of scorpion venom : an experimental study of the effects of second challenge with scorpion venom. *Intensive Care Medicine* 2005;31:441-46.
- Khatabi A oulaymani –Bancheikh R et al. Classification of clinical consequences of scorpion sting: consensus development. *Trans Roy Soc Trop Med Hyg* 2011;105:364-69.
- Upadhyaya Y. Ashtang Hridaya of Acharya Vagbhat. 1st edition. Varanasi; Chaukhamba Sanskrit Sansthan ; Reprint 2005:587
- Sonare K. Chalach S. Phytochemical Evaluation of Maha Agada; ayurpub; 2019;4(4):1279-1285
- Upadhyaya Y. Ashtang Hridaya of Acharya Vagbhat. 1st edition. Varanasi; Chaukhamba Sanskrit Sansthan ; Reprint 2005:588, p. 224
- Mahanta M, Mukharjee AK. Neutralization of lethality, myotoxicity and toxic enzymes of *Naja kaouthia* venom by *Mimosa pudica* root extracts. *J Ethnopharmacol* 2001;75:55-60
- Paget GE, Barnes JM. Evaluation of Drug activities. In: Lawrence DR, Bacharach AL, editors. *Pharmacometrics*. Vol. 1. New York: Academic Press; 1969: p. 161.
- Brahmane RI, Pathak SS, Wanmali VV, Salwe KJ, Premendran SJ, Shinde BB. Partial in vitro and in vivo red scorpion venom neutralization activity of *Andrographis paniculata*. *Pharmacognosy Res*. 2011;3: 44–8.
- Kankonkar RC, Kulkurni DG, Hulikavi CB. Preparation of a potent anti-scorpion-venom-serum against the venom of red scorpion (*Buthus tamalus*). *Journal of postgraduate medicine*. 1998;1;44(4):85.
- Vasconcelos F, Lanchote VL, Bendhack LM, Giglio JR, Sampaio SV, Arantes EC. Effects of voltage-gated Na⁺ channel toxins from *Tityus serrulatus* venom on rat arterial blood pressure and plasma catecholamines. *Comp Biochem Physiol C Toxicol Pharmacol*. 2005;141:85–92.
- Kankonkar RC, Kulkurni DG, Hulikavi CB. Preparation of a potent anti-scorpion-venom-serum against the venom of red scorpion (*Buthus tamalus*). *Journal of postgraduate medicine*. 1998;1;44(4):85.
- Dodke PC, Pansare TA. Ayurvedic and Modern aspect of *Terminalia chebula* Retz. Haritaki An Overview. *International Journal of Ayurvedic and Herbal Medicine*. 2017;7(2):2508-17.
- Amalraj A, Gopi S. Medicinal properties of *Terminalia arjuna* (Roxb.) Wight & Arn.: a review. *Journal of traditional and complementary medicine*. 2017;1;7(1):65-78.
- Tasduq SA, Singh K, Satti NK, Gupta DK, Suri KA, Johri RK. *Terminalia chebula* (fruit) prevents liver toxicity caused by sub-chronic administration of rifampicin, isoniazid and pyrazinamide in combination. *Human & experimental toxicology*. 2006;25(3):111-8.
- Riaz M, Asghar A, Rashid R, Shahzad-ul-Hussan S. Treasures hunt in old mines: *Terminalia chebula*-Based traditional herbal medicinal products. *The Natural Products Journal*. 2015 Dec 1;5(4):252-67.
- Suchalatha S & Shyamala CS, Protective effect of *Terminalia chebula* against experimental myocardial injury induced by isoproterenol, *Indian Journal of Experimental Biology*, 2004;42: 174-8
- Vaidya B.G; Nighantu Adarsha Vol.I; Chaukhamba Bharati Academy Varanashi; Reprint 2007:551-553.
- Lavekar G.S; Database on medicinal plant used in Ayurveda and Siddha; Central council for research in Ayurved and Siddha, Department of Ayush ministry of health and family welfare Government of India. Vol.8: 2008, p.445
- Sah S P, Mathela C M and Chopra K. Elucidation of possible mechanism of analgesic action of *Valeriana wallichii* D C. (Patchouli alcohol) in experimental animal models. *Indian Journal of Experimental Biology*, 2010;48(3):289-293.
- Khuda F, Iqbal Z, Zakiullah, Khan A, Nasir F. Antimicrobial and anti-inflammatory activities of leaf extracts of *Valeriana wallichii* D C. Pakistan

- Journal of Pharmaceutical Sciences, 2013; 26(3): 451–4.
28. Sharma P.; Dravyaguna Vigyan; Chaukhamba Bharati Academy Varanasi; Volume-II; Reprint 2005, p.331
 29. Kiuchi F, Iwakami S, Shibuya M, Hanaoka F, Sankawa U. Inhibition of prostaglandin and leukotriene biosynthesis by gingerols and diarylheptanoids. Chemical and Pharmaceutical Bulletin. 1992;25;40(2):387-91.
 30. Nurtjahja-Tjendraputra E, Ammit AJ, Roufogalis BD, Tran VH, Duke CC. Effective anti-platelet and COX-1 enzyme inhibitors from pungent constituents of ginger. Thrombosis research. 2003;1;111(4-5):259-65.
 31. Sharaky AS, Newairy AA, Kamel MA, Eweda S; Protective effect of ginger extract against bromobenzene-induced hepatotoxicity in male rats.; Food Chem Toxicol, 2009;47(7):1584-1590.
 32. Kim HW, Murakami A, Abe M, Ozawa Y, Morimitsu Y, Williams MV, Ohigashi H.; Suppressive effects of mioga ginger and ginger constituents on reactive oxygen and nitrogen species generation, and the of inducible pro-inflammatory genes in macrophages.; Antioxid Redox Signal; 2005;7:1621–1629.
 33. Lavekar G.S; Database on medicinal plant used in ayurveda and siddha; Central council for research in Ayurved and siddha, Department of Ayush ministry of health and family welfare Government of India. 2008, p. 118
 34. Negi A.; Analgesic activity of fruit decoction of Citrus medica Linn.; Journal of Pharmacy Research; 2010;3(9):2119-21
 35. Joshi AI, Tirgar PR. Evaluation of cardiotoxic effect of *Citrus medica* in congestive heart failure; An international journal of pharmaceutical sciences; 2013; 4(4): 1-10.
 36. Yadavji Trikamaji V. Charaksamhita of Agnivesha of Charaka & Dhudhbala with Ayurveda Dipika commentary by Chakrapanidatta.Reprint.Varanasi; Chaukhamba Surbharati Prakashan; 2008. p.432
 37. Rajput D, Patgiri B. Ayurvedic view on heavy metal poisoning with special reference to Naga bhasma incinerated lead, a literary study. Int J Pharm Biol Arch. 2013;4(1):41-5.

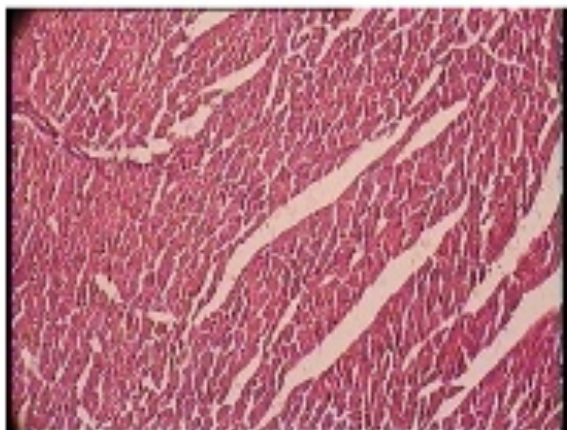
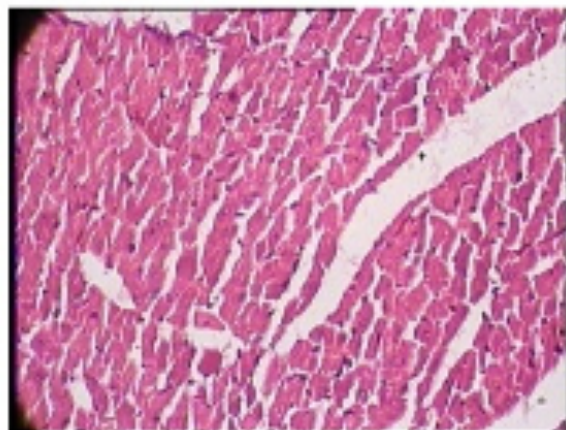
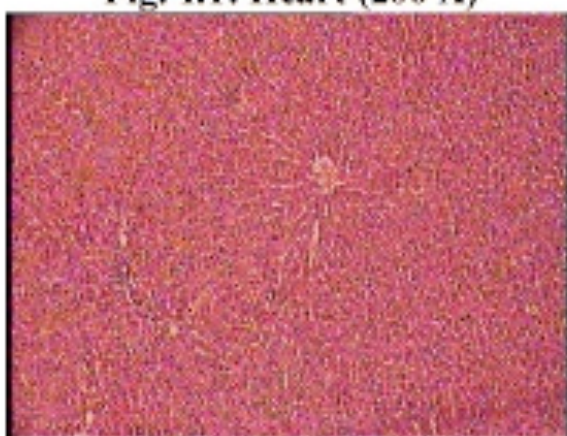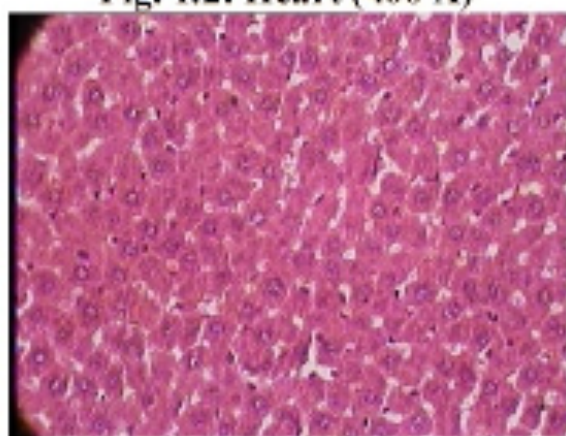
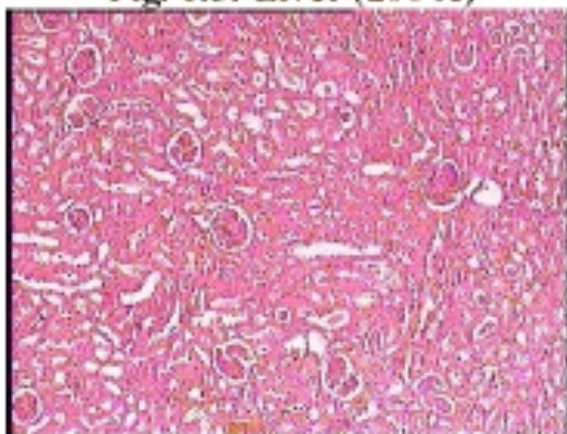
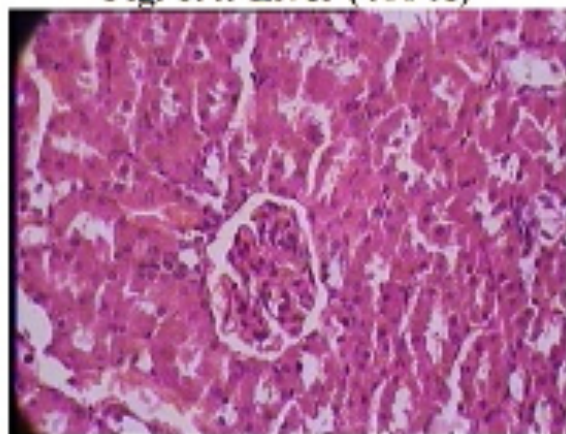
Figure 1: Histopathological study of group- i (control group)**Fig. 1.1: Heart (200 X)****Fig. 1.2: Heart (400 X)****Fig. 1.3: Liver (200 X)****Fig. 1.4: Liver (400 X)****Fig. 1.5: Kidney (200 X)****Fig. 1.6: Kidney (400 X)**

Figure 2: Histopathological study of group- 2 (test group 1)

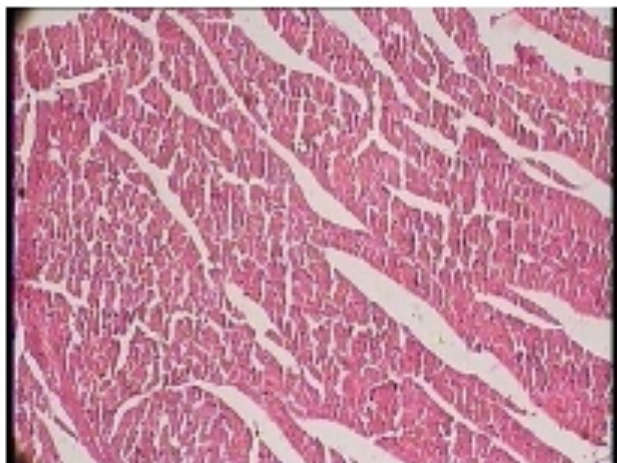


Fig. 2.1: Heart (200 X)

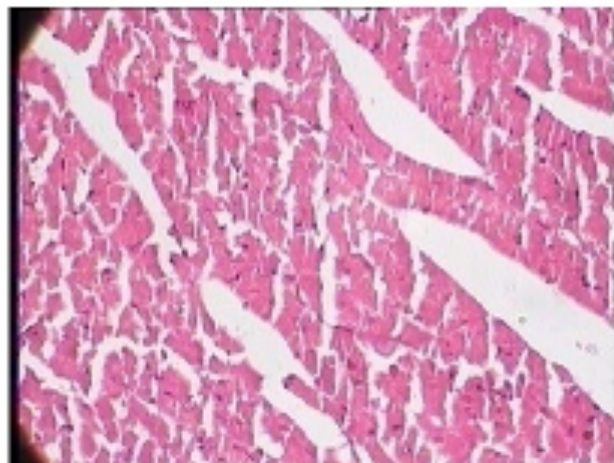


Fig. 2.2: Heart (400 X)

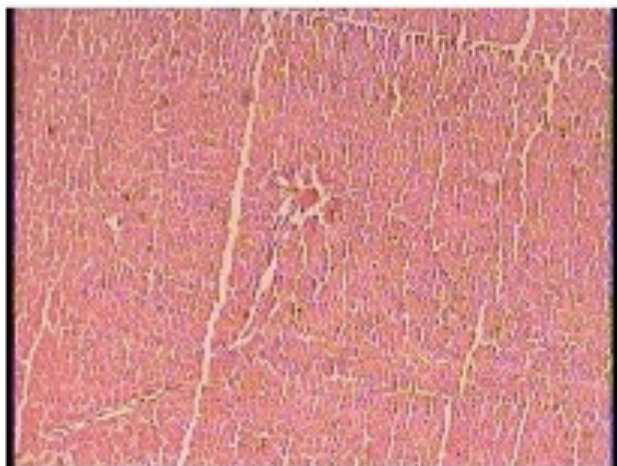

Fig. 2.3: Liver (200 X)

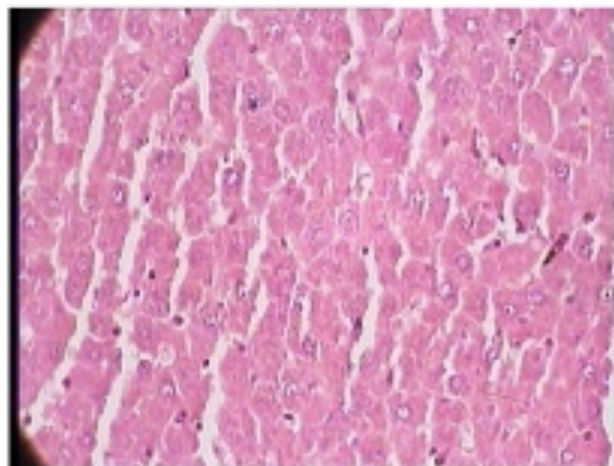


Fig. 2.4: Liver (400 X)

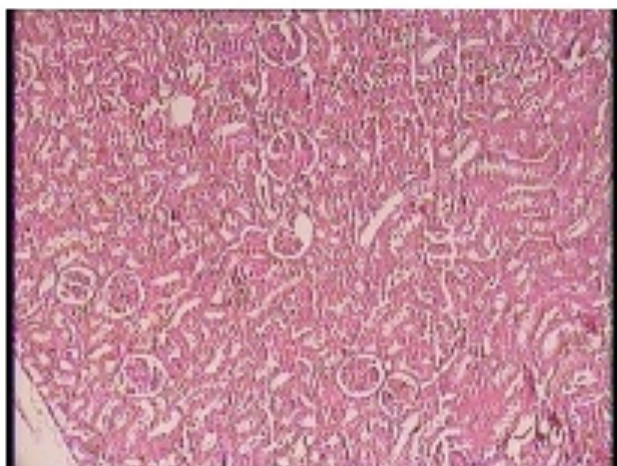


Fig. 2.5: Kidney (200 X)

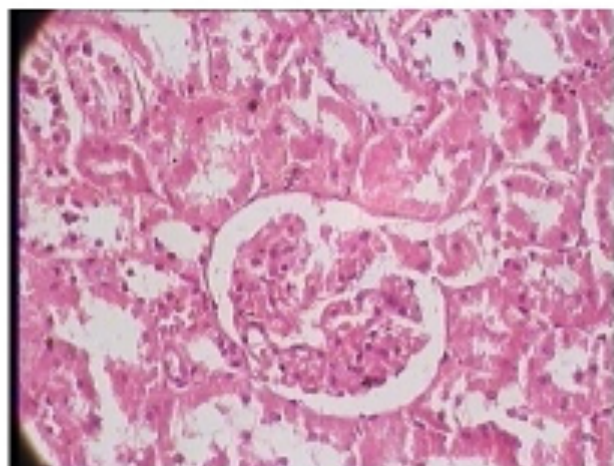


Fig. 2.6: Kidney (400 X)

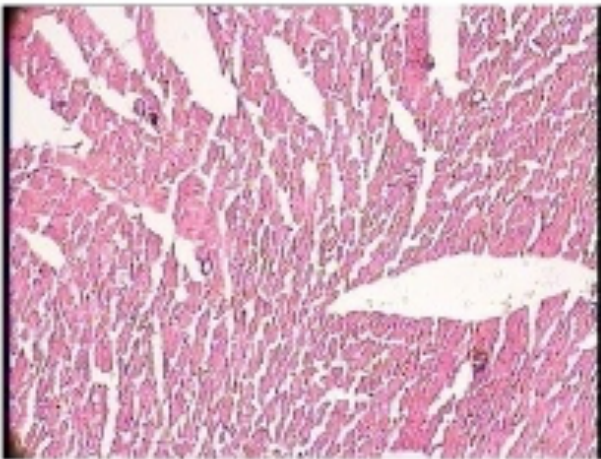
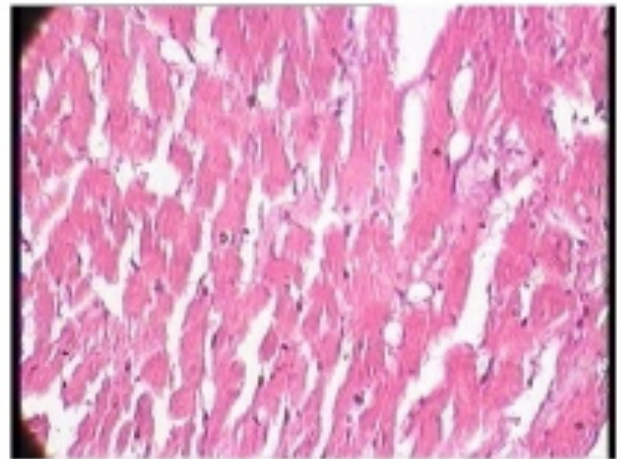
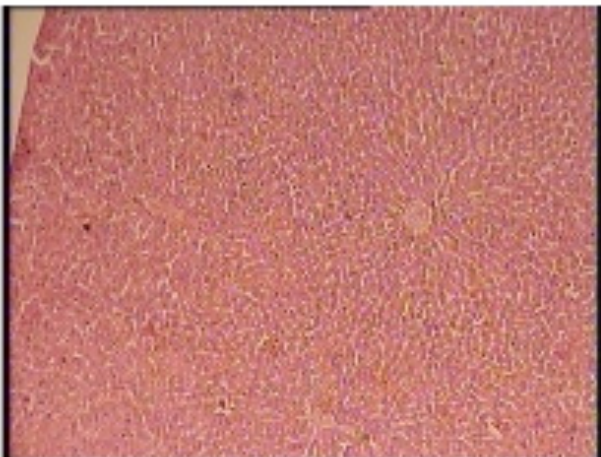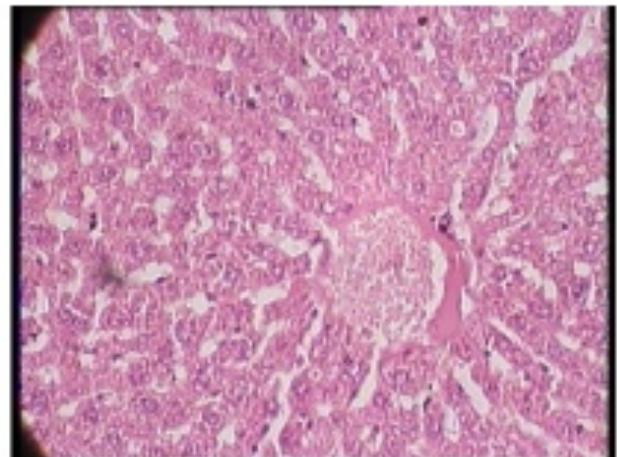
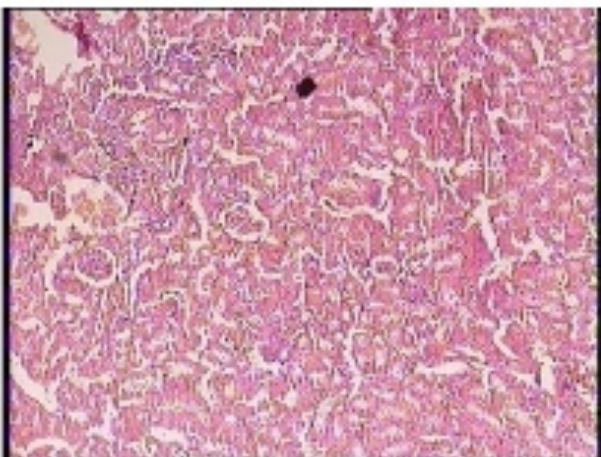
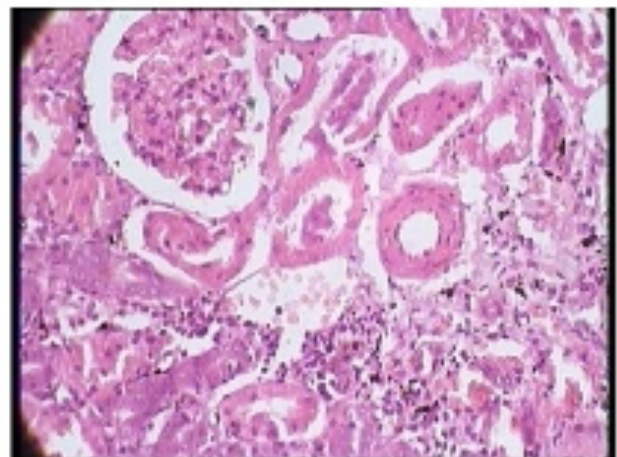
Figure 3: Histopathological study of group- 3 (standard group)**Fig. 3.1: Heart (200 X)****Fig. 3.2: Heart (400 X)****Fig. 3.3: Liver (200 X)****Fig. 3.4: Liver (400 X)****Fig. 3.5: Kidney (200 X)****Fig. 3.6: Kidney (400 X)**

Figure 4: Histopathological study of of group- 4 (test group 2)

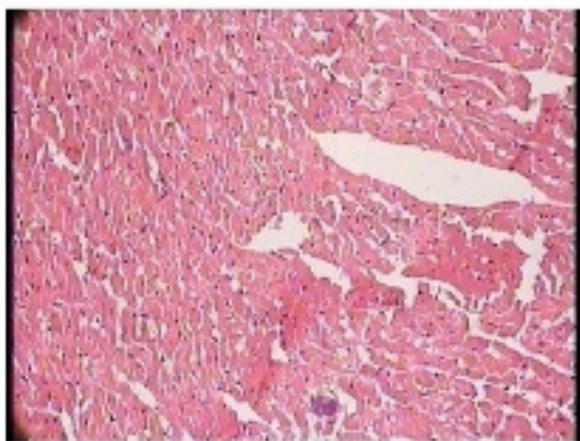


Fig. 4.1: Heart (200 X)

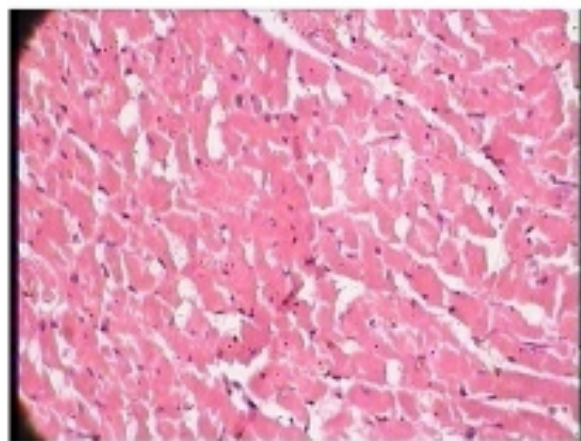


Fig. 4.2: Heart (400 X)

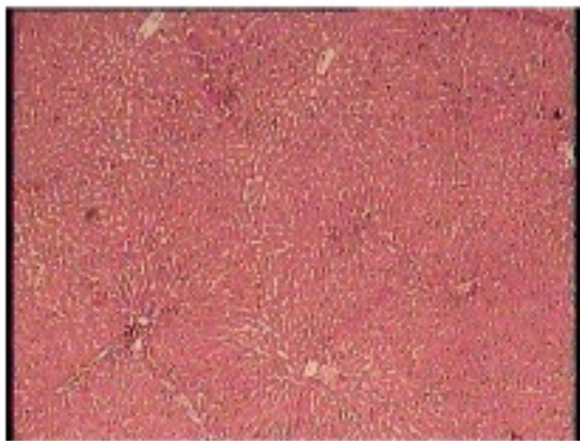


Fig. 4.3: Liver (200 X)

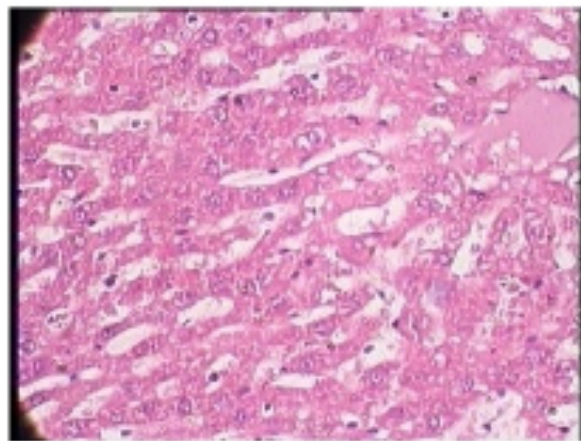


Fig. 4.4: Liver (400 X)

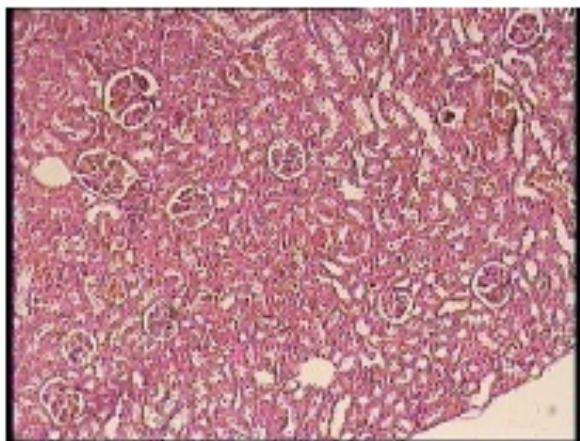


Fig. 4.5: Kidney (200 X)

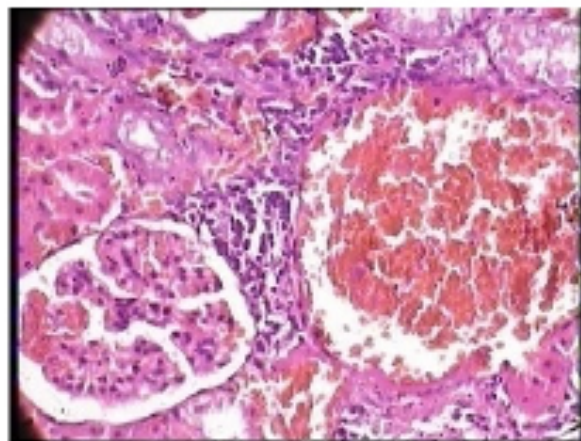


Fig. 4.6: Kidney (400 X)
